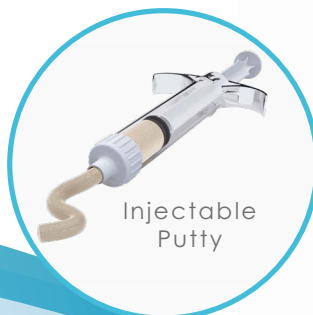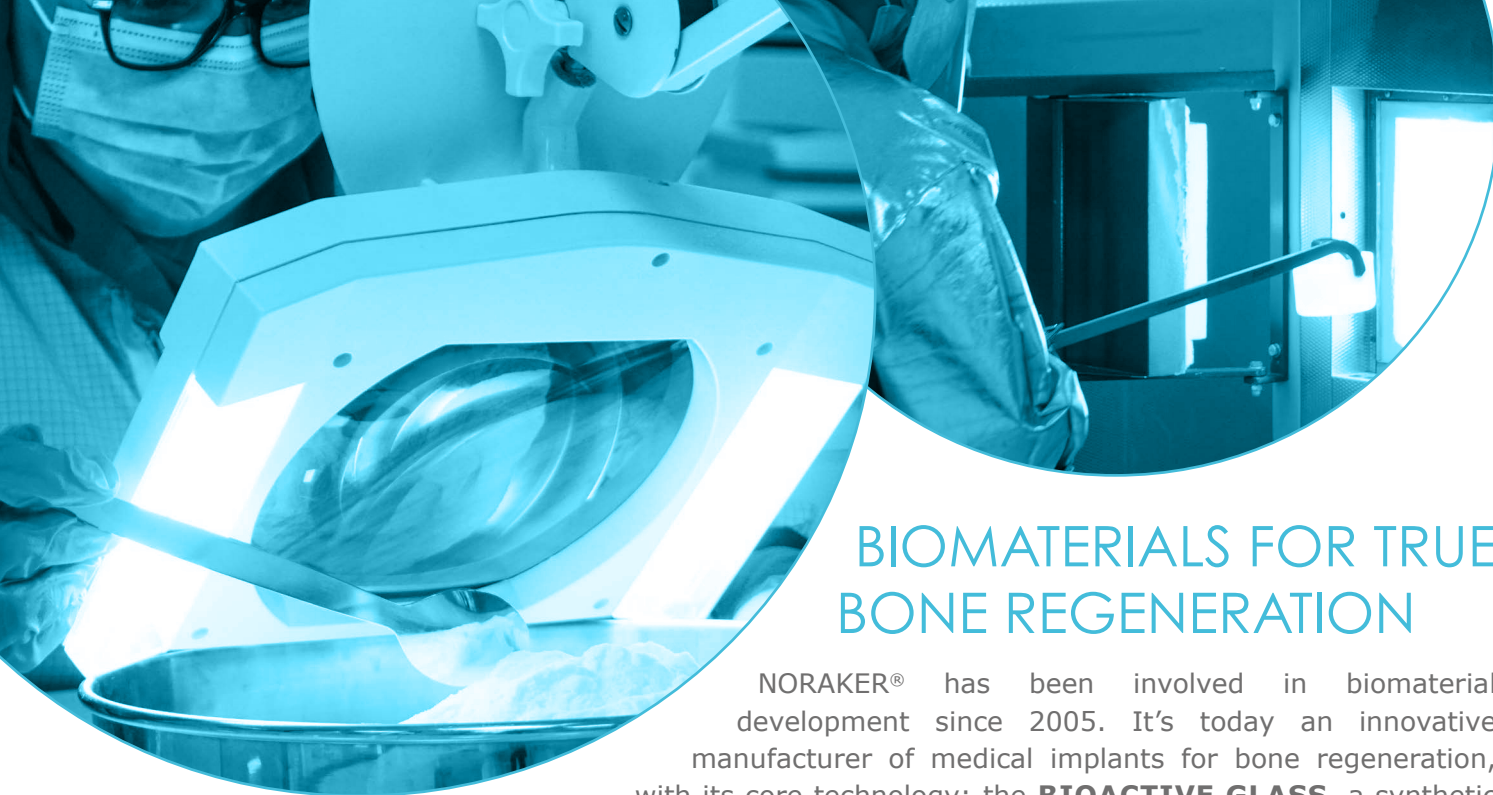


# AktiBone<sup>™</sup>

## Bioactive Bone Substitute

Synthetic Bone Substitutes  
Bioactive Glass Technology





## BIOMATERIALS FOR TRUE BONE REGENERATION

NORAKER® has been involved in biomaterial development since 2005. It's today an innovative manufacturer of medical implants for bone regeneration, with its core technology: the **BIOACTIVE GLASS**, a synthetic bioresorbable ceramic.

### COMPOSITION

AktiBone™ Substitutes are made of bioactive glass. This ceramic is composed of Silicium, Calcium, Sodium and Phosphorous, minerals naturally present in the human body. The natural composition allows an excellent biocompatibility. <sup>1, 2, 3</sup>

### ADVANTAGES

The Bioactive glass has been classified by Dr Larry Hench Class A bone substitute, whereas inert materials, such as hydroxyapatites or calcium phosphate, are Class B. <sup>8</sup>

### PERFORMANCES

The Bioactive glass has already proven its clinical performances: more particularly, its ability to fill a bone defect and gradually being replaced by a functional tissue. <sup>4</sup>

### INDICATIONS AND TARGET POPULATION

Loss or lack of bone substance for bone defects of traumatic, pathological, or surgical origin when autologous solutions are not applicable or sufficient. AktiBone™ is a synthetic, bioactive, and absorbable device for filling, reconstruction and/or fusion of bone defects or gaps in the skeletal system in children and adult populations.

## Compositional diagram for bone bonding

Biological properties according to quantity of silicium, sodium and calcium with 6% of phosphorous. <sup>5, 10</sup>

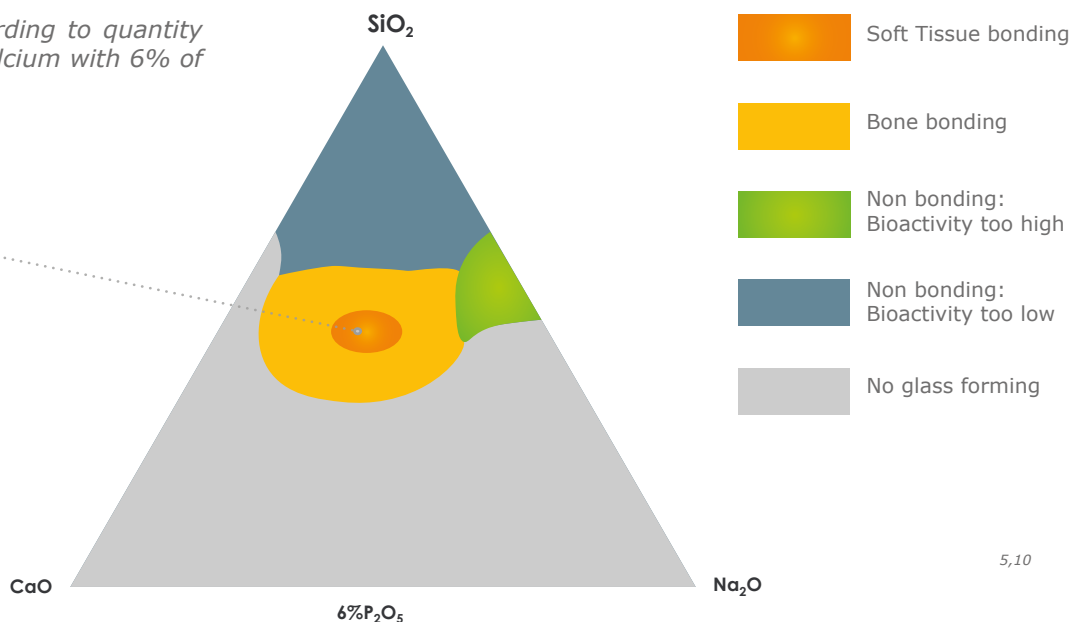
**AktiBone™**  
Bioactive glass 45S5

SiO<sub>2</sub> : 45%

Na<sub>2</sub>O : 24.5 %

CaO : 24.5 %

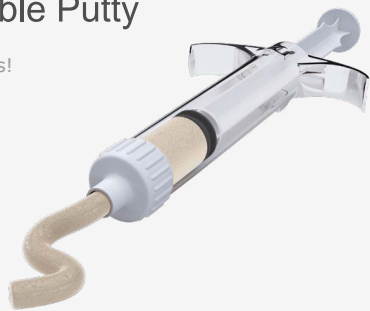P<sub>2</sub>O<sub>5</sub> : 6 %



# AktiBone™ range : Injectable Putty and Granules


## AktiBone™ Injectable Putty

Open & Press!



## AktiBone™ Granules

To mix with patient's blood,  
patient's bone or saline  
solution



INDICATION	PERFORMANCE ACHIEVED	BENEFITS	RISK
Fusion or reconstruction of deformities and degenerative bone pathologies in orthopaedic	100% filing at 12 months	Improvement of patient quality of life. No bone harvest	No complication related to AktiBone G or IP identified
Filling and reconstruction of bone defects due to resection of tumors, cyst or infection and in case of prosthetic revision	100% filing 88% reconstruction minimum At 12 months	Improvement of patient quality of life. No bone harvest	No complication related to AktiBone G or IP identified
Filling after surgical bone defect (donor sites after removal of autograft, trepanation, ...)	100% filing at 12 months	Improvement of patient quality of life.	No complication related to AktiBone G or IP identified

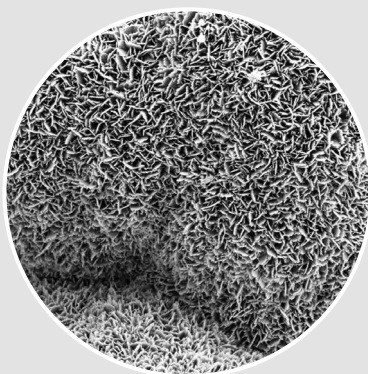
## MECHANISM OF ACTION



### 1. Easy to use

*Granules:* very cohesive and hydrophylic when mixed with saline serum, patient blood or autologous bone.

*Injectable Putty:* Ready to use, can be injected through the syringe.



### 2. Ionic exchanges


At 14 days: formation of an active biological mineral layer of calcium phosphate, with similar composition and structure as human bone. <sup>1, 3, 5</sup>

# Did you know?

Bone substitutes are classified into an Index of Bioactivity (only demonstrated by in-vitro study).<sup>8</sup>

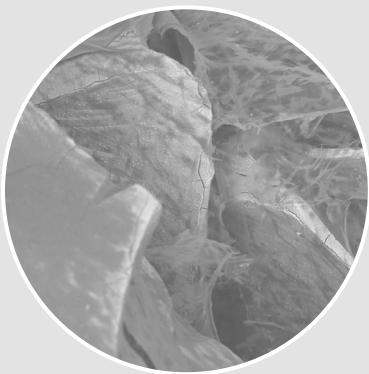Class A	Class B
Osteoconduction + Osteoproduction	Osteoconduction
Bioactive Glass 45S5	HA, $\beta$ TCP

## Bioactivity study - In vitro evaluation for apatite-forming ability. <sup>10</sup> (in vitro study)



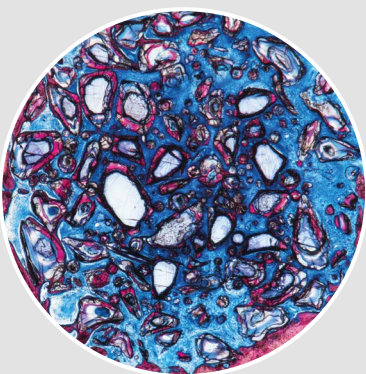
SEM images of (a) AktiBone™ Granules 05.1 and (b) AktiBone™ Injectable Putty a magnification of x50 (left) and X 10,000 (right) after 28 days of immersion in SBF (testing according to ISO 23317:2014).

The surface of the granules presents cracks at x50 and needle-like structures at X 10,000. This is characteristic of hydroxyapatite formation. This evaluation of apatite-forming ability on implant material in SBF is useful for evaluating its in vivo bone-bonding ability.

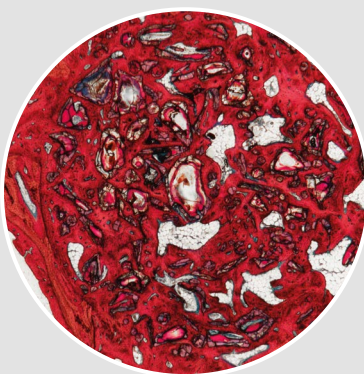


### 3. Scaffold formation

At 21 days:  
The increased concentration of minerals induces a carbonated hydroxyapatite layer (CHA). <sup>2, 4, 6</sup>



At 4 weeks:  
Fibrous collagenous tissue (blue) is spread in the defect and surrounds the bone substitute. A centripetal bone neoformation (dark pink) is already observed. <sup>7</sup>  
(In vivo study)



### 4. Bone Regeneration

At 12 weeks:  
New bone (dark pink) is present in most of the initial defect, with adipocytic bone marrow, an indicator of mature trabecular bone. <sup>7</sup> (In vivo study)

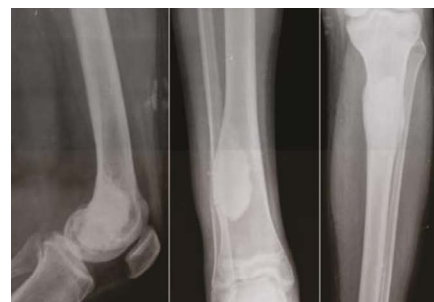

## 1\_ Is a Bioceramic GlassBone™ Graft Superior to Spongy Allografts in Femoral and Tibial Benign Bone Lesions? J Tepecik Educ Res Hosp 2022 İlyas G, Kaya A, İncesu M

**METHODS:** Forty-seven patients, who applied to our hospital between the years 2007 and 2013; who received curettage-grafting for benign bone lesions in the long bones carrying lower extremity weight were examined retrospectively.

**RESULTS:** In the bioceramic glass bone graft group, an increased average consolidation ratio, which is statistically significant compared to the spongy allograft group ( $p=0.002$ ), was observed. When the fibrous dysplasia patients were considered a subgroup, the consolidation ratio in the bioceramic GlassBone™ graft group was found to be significantly high compared to the spongy allograft group ( $p=0.029$ ).

**CONCLUSION:** Bioceramic glass bone grafts are bone filler materials that hold radiologically superior and clinically similar results compared to spongy allografts. Having a statistically significant radiological consolidation success in fibrous dysplasia, which is a benign aggressive tumor, bioceramic glass bone grafts may be thought to be capable of being an advantage option for benign aggressive tumors.



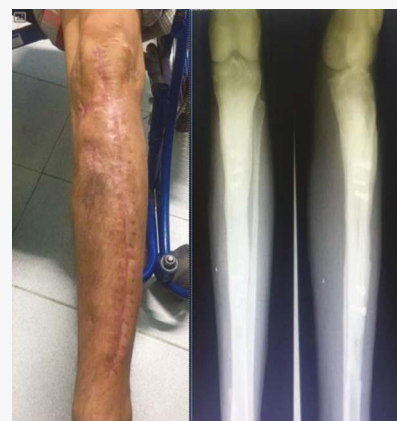Bioceramic bone graft samples

## 2\_ Chronic Tibial Osteomyelitis; Use of Bioactive Glass as an Alternative of Treatment. Report of a Case. International Journal of Medical Science and Dental Research (2022) Mora-Zúñiga A, Cárdenas-Arellano F, Cruz-Munguía JD, Hernández-Carrillo JE

**METHODS:** 42-years-old male with a diagnosis of chronic tibia osteomyelitis, with sequelae of previous surgical interventions, multiple antibiotic treatments and type IV B classification by Cierny-Mader. A two-stage surgical treatment was chosen. Firstly, extensive bone and soft tissue debridement, placement of cement beads medicated with amikacin in the medullary cavity and osteoclast system for irrigation with vancomycin. In the second stage, free fibular bone grafting, fixation and stabilization with screws, bioactive glass (GlassBone™ Granules) placement in areas of interface between stabilized fibula and posterior tibial cortex. Safety, quality of life and osteointegration of graft were evaluated.

**RESULTS:** At 3 months, the patient walk without support and laboratory tests are within normal parameters. Radiography shows an osseointegration of the fibula into the tibia. At 12-months follow-up, the patient has no evidence of infection and has recovered 90% of the function of the affected limb.

**CONCLUSION:** The surgical management in two time, the use of medication beads, bone graft and the use of bioactive glass, achieved a complete eradication of the infection and favourable clinical evolution with optimal functional recovery of affected limb.



Closure of fistulas and surgical wound without evidence of exudates. Bone osseointegration of the fibula in the tibia.

## 3\_ The impact of bone graft type used to fill bone defects in patients undergoing ACL reconstruction with bone-patellar tendon-bone (BPTB) autograft on kneeling, anterior knee pain and knee functional outcomes.

European Journal of Orthopaedic Surgery & Traumatology (2023)

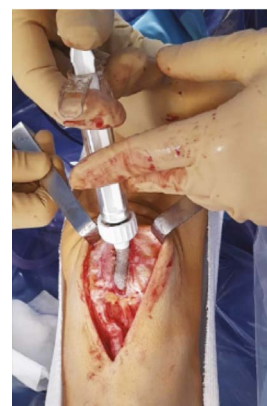Ali Fares, Alexandre Hardy, Yoann Bohu, Alain Meyer, Karam Karam, Nicolas Lefevre

**OBJECTIVE:** Analyzes of clinical data, tolerance and impact of bone substitutes used in patients operated for ACL reconstruction with technique by bone-patellar tendon-bone graft.

**METHODS:** A prospective monocentric cohort study conducted from January 2018 to March 2020. 102 patients who underwent ACL reconstruction and were divided into three groups based on type of bone substitute. The Bioactive glass 45S5 ceramic GlassBone™ (GB) (36 patients), collagen and hydroxyapatite bone void filler in sponge form Collapat® II (CP), and treated human bone graft Osteopure®(OP) bone substitutes. A questionnaire completed in the 2nd post-operative year included: the ability to kneel, the presence of donor site pain, and the palpation of a defect.

**RESULTS:** In terms of Kneeling pain, the percentage of GB and CP patients' who kneel with ease were much higher than that of OP patients (77.78%, 76.5% vs 65.6%, respectively). There was no difference in anterior knee pain between the groups. No postoperative complications were observed with GB and the defect was 100% filling. The IKDC and Lysholm score was significantly improved in all three groups compared to preoperative status.

**CONCLUSION:** The use of GlassBone™ to fill bone defects in ACL-R patients, using with a bone-patellar tendon-bone autograft, presents no complications, rejection or infection. The use of GlassBone™ significantly reduces kneeling pain (77.78% of patients who kneel easily). At two years' follow-up, the clinical and functional results (subjective IKDC and Lysholm) are significantly improved.



Intra-operative photograph showing the patellar defect being filled with Glassbone.

## Bioactive Bone Substitutes

References	Granule size	Volume
<b>AktiBone™ Granules</b>		
XAK-GM0.5	0.5 – 1.0 mm	0.5 cc
XAK-GM1.0	0.5 – 1.0 mm	1.0 cc
XAK-GM5	0.5 – 1.0 mm	5.0 cc
XAK-GL1.0	1.0 – 3.0 mm	1.0 cc
XAK-GL5	1.0 – 3.0 mm	5.0 cc
XAK-GL10	1.0 – 3.0 mm	10.0 cc
XAK-GL16	1.0 – 3.0 mm	16.0 cc
<b>AktiBone™ Injectable Putty</b>		
XAK-IP1.0	0.1 - 0.7 mm	1.0 cc
XAK-IP1.5	0.1 - 0.7 mm	1.5 cc
XAK-IP2.5	0.1 - 0.7 mm	2.5 cc
XAK-IP5.0	0.1 - 0.7 mm	5.0 cc
XAK-IP6.0	0.1 - 0.7 mm	6.0 cc
XAK-IP10 *	0.1 - 0.7 mm	10.0 cc

\* Not available for France

Loss or lack of bone substance for bone defects of traumatic, pathological or surgical origin when autologous solutions are not applicable or sufficient in orthopaedics, neurosurgery, cranio maxillo facial and otorhinolaryngology surgery in children and adult population.

Main indications:

- ORTHOPAEDIC SURGERY
- SPINAL SURGERY
- CMF / ENT SURGERY

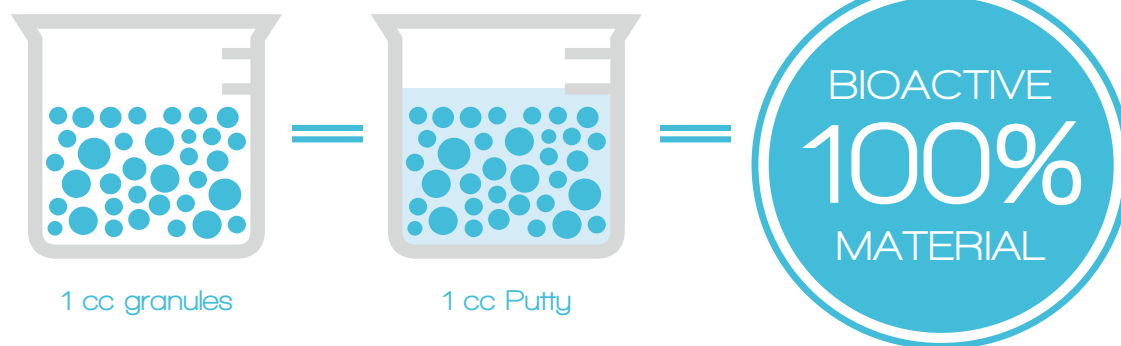
# AktiBone™

AktiBone™, bone graft substitutes are medical devices class III (CE 0459), manufactured by NORAKER®.

AktiBone™ products are indicated to fill bone defects.

Carefully read the instructions supplied with the product.

1. Tsigkou, O. et al. *Biomaterials*. 2009;**30**:3542-50
2. Oonishi, H. et al. *J. Biomed. Mater Res*. 2000;**51**:37-48.
3. Jones, J.R. *Acta Biomaterialia*. 2013;**9**:4457-4486.
4. Xynos, I.D. et al. *Calcif Tissue Int*. 2000;**67**:321-9.
5. Hench, L.L. *J. Mater Sci: Mater Med*. 2006;**17**:967-978.
6. Jell, G. et al. *J. Mater Sci : Mater Med*. 2006;**17**:997-1002.
7. Data on file at NORAKER®, study on sheep.
8. Hench, L.L. *Biomaterials* 1998;**19**:1419-1423.
9. Clinicals and technicals datas on file at NORAKER®.
10. Datas on file at NORAKER® : In vitro study



NORAKER® is a French manufacturer specialized in the research and development of innovative products based on the 45S5 bioactive glass technology for medical applications.

60 Av. Rockefeller  
69008 Lyon  
France

Tel: +33 (0)4 78 93 30 92  
Fax: +33 (0)4 72 35 94 37

contact@noraker.com

Made in France by NORAKER®